

# TRANSACTIONS

OF THE

## PHILADELPHIA ACADEMY OF SURGERY

STATED MEETING HELD OCTOBER 7, 1929

The President, DR. ASTLEY P. C. ASHHURST, in the Chair

CALVIN M. SMYTH, JR., M.D., Recorder

### DUODENAL ULCER COMPLICATING APPENDICITIS

DR. HUBLEY R. OWEN presented a man, aged thirty-eight years, who was admitted to hospital May 31, 1929, with the chief complaint of acute pain in the abdomen. Twenty days before admission he had had sudden pain in his abdomen which was treated by his family physician and improved. Forty-eight hours prior to admission he took two doses of magnesium sulphate following which the pain became aggravated and he was admitted to the hospital. On admission the patient showed evidence of having very acute abdominal pain. He complained of persistent nausea and vomiting for the last forty-eight hours. His entire abdomen was rigid and exquisitely tender. There was no abnormal breathing. Knees were flexed on the abdomen. The temperature was 103 by axilla; pulse 140; respirations 31. No leucocyte count was made. Operation revealed a general peritonitis. The appendix was readily accessible and was removed. Three tubes and one cigarette drain were inserted; one tube leading to the floor of the pelvis.

The patient's progress, following the operation, was entirely uneventful. He continued to improve until fifteen days after operation when he was seized with severe generalized abdominal pain which was more severe in the epigastrium. There was board-like rigidity.

The leucocyte count showed 20,000 per centimetre with 88 per cent. of polymorphonuclears; lymphocytes 7 per cent.; transitionals 5 per cent. His temperature, which at 8 A.M. had been 98, rose to 103; and pulse, which at 8 A.M. had been 80, at 5 P.M. was 140. At operation an incision was made to the left of the mid-line in the epigastrium. The upper abdomen was a mass of recent adhesions. The duodenum presented a small perforation of apparently an acute ulcer. The ulcer was encircled with a purse-string suture and a piece of omentum was sewn over the anterior portion of the duodenum. The upper abdomen was drained. At the time of the second operation there were eight drainage tubes—one to either renal region; two in the region of the appendix; two in the region of the liver; and two supra-pubic.

The patient had somewhat of a stormy convalescence from his second operation, but was finally discharged from the hospital thirty-seven (37) days after his second operation. It is interesting to note that there was absolutely no history prior to the operation of symptoms suggesting gastric or duodenal ulcer nor has he had any symptoms referable to his abdomen since the operation.

The speaker remarked that the association of sub-acute and chronic disease of the appendix with lesions of the upper abdomen is well recognized. Gastric and duodenal ulcers, gall-bladder disease, pancreatic disease and lesions of the liver may complicate appendicitis. Acute infection of the gall-bladder and acute lesions of the liver are not uncommon complications of acute appendicitis. Acute manifestations of gastric and duodenal ulcers

## PHILADELPHIA ACADEMY OF SURGERY

are apparently rare complications. Rupture of the duodenal and gastric ulcers complicating acute appendicitis is seldom mentioned in the literature. Subphrenic and subhepatic abscesses and abscesses of the liver itself are far more frequent complications of acute appendicitis, than is rupture of gastric or duodenal ulcer. Abscess of the liver probably occurs as a direct transmission of bacteria through the lymphatics or through the portal vein. Ulceration of the duodenum secondarily to acute appendicitis is probably a blood stream infection due to septic emboli. Moore, quoted by Royster, reported a case of perforation of gastric ulcer during an attack of acute appendicitis (*Glasgow Medical Journal*, April, 1923). Zweig assumes that duodenal ulcer complicating appendicitis is the result of retrograde embolus. Hematemesis may be a post-operative symptom of acute appendicitis. Royster mentions three instances of hematemesis after operation for acute gangrenous appendicitis and states that "undoubtedly in some cases there are erosions of the gastric mucosa or even acute ulcers which heal without organic remains." Dielafoy, quoted by Royster, mentions having found ecchymotic patches in the stomach mucous membrane produced, he says, by appendiceal toxins, and the hæmorrhage is precipitated by evident ulceration of the arterioles ramifying under the muscularis mucosæ. Woolsey, quoted by Royster, estimated gastric hæmorrhage as occurring in 2 per cent. of cases of appendicitis. Kummel reported a case of acute appendicitis with a hæmorrhage five days after operation. The patient died on the eighth day and an ulcer of the duodenum seven by eleven centimetres was found in the duodenum. He attributed the origin of the ulcer to embolism. Phifer reported a similar case occurring on the second day after operation. He also "judged the hæmorrhage to be from thrombosis and embolism in the intestinal walls."

### THE ASSOCIATION OF VERTEBRAL FRACTURES WITH FRACTURES OF THE OS CALCIS

DR. J. GERSHON-COHEN (by invitation) remarked that fracture of the os calcis is frequently encountered in the active surgical service of the Graduate Hospital of the University of Pennsylvania. There are various causes described in different kinds of fractures of this bone which have led to multiple and often confusing classifications. Good results in the treatment of these fractures are generally considered to be obtainable in only about 20 to 25 per cent. and the complication which he proposed to deal with here makes the treatment even more difficult.

Six cases are here reported out of a series of sixty-two cases of fractured os calcis treated at the Graduate Hospital during the past five years, in which a fracture of a vertebra resulted from the same accident that caused the fracture of the os calcis. Twenty of the sixty-two cases had X-ray taken of the vertebræ. The remaining six examined röntgenologically were cases with a history of a fall from a height, and all six showed compression fracture of the body of one or more vertebræ. An interesting phenomenon was the absence or relative lack of commensurate subjective symptoms aris-

## VERTEBRAL FRACTURES WITH FRACTURES OF THE OS CALCIS

ing from the vertebral injury, which phenomenon has recently been recorded by Dr. Lever Stewart.

CASE I.—A woman, thirty-three years of age. Colored housewife. Jumped out of a second-story window and landed on her feet. She was admitted to the Receiving Ward of the Graduate Hospital, February 2, 1928, complaining of swelling and pain of the right foot and ankle and slight pain in the sacral region radiating laterally and forward to the right groin. Physical examination was negative except for tenderness along the lumbar spine, with pain in the right groin; swelling of the right foot, with crepitus and tenderness in the right os calcis. Röntgen examination revealed a compression fracture of the right os calcis and a fracture through the anterior superior portion of the body of the second lumbar vertebra. The röntgen examination of the lumbar vertebra was made because of the previous findings in cases of this character and not because the resident physician believed that the subjective symptoms or the physical findings were sufficiently characteristic to warrant a diagnosis of fracture of the bodies of any of the lumbar vertebræ.

CASE II.—A white male, fifty-nine years of age, who fell a distance of approximately twenty feet from a scaffold on which he was working, landing on his feet. He was admitted to the Receiving Ward, May 28, 1927, with a compound fracture of the right tibia and fibula and a fracture of the left external malleolus with pain and tenderness of the left foot. He had no symptoms referable to the spine except generalized pains and aches over the entire body. Röntgen examination of the spine was made, however, and revealed a fracture of the body of the twelfth dorsal vertebra. This patient died forty-six days after admission to the hospital of acute intestinal obstruction which was confirmed by autopsy.

CASE III.—A man, thirty-nine years of age, who fell eighty feet from the scaffold on which he was working. He landed on his feet and was admitted to the hospital July 31, 1924, with swelling of the left ankle and foot and of the right foot. There were no complaints referable to the spine, but nevertheless röntgen examination was made of the spine at the same time the other examinations were made. There was a compressed fracture of the os calcis of both feet along with fractures through the right scaphoid, the fourth left metatarsal, through the internal condyle of the left femur and of the body of the second lumbar vertebra.

CASE IV.—A woman, twenty-eight years of age. A housewife who during a nightmare walked out of a second-story balcony window. After landing, she got up and walked into her house. This patient complained of pain in the right foot and of some back pain, but not enough at the time of the examination to clinically diagnose fracture of a vertebral body. On röntgen examination, a compressed fracture of the right os calcis and of the body of the second lumbar vertebra was found.

CASE V.—A man, nineteen years of age, who fell from a third-story window. He landed on his feet and sustained fracture of his right os calcis, astragalus, both bones of the right leg and the first, second and third lumbar vertebral bodies. His limb injuries were so marked that his back was relatively painless while reclining quietly in bed.

CASE VI.—A man, aged thirty-four years, who fell through an open manhole landing on his feet. A compressed fracture of the right os calcis was present and this alone was treated for two days when he began to complain of some pain in the lumbar region. Röntgen examination then revealed a fracture of the first lumbar vertebra.

The reporter presented these cases to show the importance of having all cases of fracture of os calcis, produced by a fall from a height, examined röntgenologically for vertebral body fractures. In this examination the lateral view of the spine is by far the more important.

DR. WILLIAM BATES remarked that of the sixty-two cases treated in the period of five years, six of them showed this rather serious complication.

## PHILADELPHIA ACADEMY OF SURGERY

If only 10 per cent. of all os calcis fractures were to show this additional lesion, one would still be justified in X-raying the spine of each one of them. However, of the twenty cases that had pictures taken of the spine, six of them showed a crushed vertebra, therefore the percentage immediately rises from 10 to 30 per cent.

In going over the histories of the twenty cases only six gave a history of a fall from a height; the remainder of the X-rays were taken because of multiple injuries and the possibility of spine involvement. The percentage therefore takes an enormous leap in this small series, showing the frequency that a fracture of the os calcis from a fall from a height also had a crushed vertebra.

Recently, two cases had come to the speaker's attention from other services where both spine and os calcis were X-rayed. The os calcis was found fractured and the vertebræ were not found fractured. It will be interesting to have these two cases X-rayed at a later date and the vertebræ carefully measured for the evidence of compression may not develop immediately. In view of this, many of the forty-two cases in this series which did not have a spine X-ray will be asked to return for X-ray studies.

The second interesting point is the comparative lack of symptoms in each one of these cases, which seemed to him that it justified the advocating of a spine X-ray in every suspected fracture of the os calcis.

In the treatment of the compressed vertebræ they have been using the standard Bradford frame. The patient's height is measured and compared with the total length of the frame and the distance from the site of vertebral fracture from the tip of the head of the patient is measured. The Bradford frame is then bent at a point which will immediately underlie the fractured vertebra so that the frame at this point is raised from four and one-half to five inches from the mattress with the rest of the frame resting flat. The patient is kept in this position for a period of one month in an effort to prevent any weight from resting on the anterior portion of the vertebræ. Following this he is fitted with a brace fitting around the pelvis and extending well up on the chest to immobilize the lumbar region. This brace is worn for from three to six months, according to the severity of the compression.

### PULSATING EXOPHTHALMOS

DR. GEORGE M. DORRANCE presented a lad, sixteen years of age, who was treated by him in Cooper Hospital, Camden, through the courtesy of Doctors Mecray and Buzby.

The patient was injured in an automobile accident in December, 1928. He was admitted to the West Jersey Homeopathic Hospital, where a diagnosis of fracture of the skull was made. He was bleeding from the nose and ears. Approximately three weeks after leaving the hospital, he developed a swelling of the right eye and complained of a blowing noise in his head. He was admitted to the Cooper Hospital on March 5, 1929, suffering from marked pulsating exophthalmos. There was so much œdema of the conjunctiva that the cornea could not be seen. Doctor Crammer, the ophthalmologist on duty, reported that the eye was pushed forward a considerable distance and furthermore, he could distinctly feel an arterial pulse at

PULSATING EXOPHTHALMOS

the upper angle of the orbit. A bruit was present. Doctor Dorrance saw the patient and concurred with Doctor Crammer's findings.

On the day of the operation, April 30, 1929, he had marked protrusion of the eye and considerable œdema of the conjunctiva. The bruit was most marked on the right side of the head, but could be distinctly heard over the left eye.

Under local anæsthesia the common carotid area was exposed and a Crile's clamp was applied, gradually obliterated the lumen of the artery. When complete obliteration occurred, it was observed that the pulsation in the temporal artery ceased and the bruit likewise disappeared. The common carotid was then ligated with chromic catgut. It was noted that the eye receded slightly after the ligation. One hour after the operation, the temporal pulse returned. On the following day there was a bruit heard over the right eye. The exophthalmos was unchanged.

On May 20, under local anæsthesia, the wound in the neck was reopened with the idea of ligating a number of the branches of the external carotid. In order to determine if there was any reversal of the flow from the external to the internal carotid, clamps were applied to the internal carotid, one to the external and one to the ascending pharyngeal (Fig. 1).

By releasing the clamp upon the external carotid, it was possible to squeeze out the blood from the space between the clamps (Fig. 1-H). On reapplying this clamp, there was no blood in this space. Removing it, the blood under pressure returned in the area. Again all the blood was pressed out of this space and the external carotid clamp reapplied. On releasing the clamp on the internal carotid, the blood returned slowly in the cavity as if there was just a slight reflux. This blood was squeezed out and the internal carotid clamp reapplied. When the clamp on the ascending pharyngeal was removed the cavity refilled very quickly, but at a more reduced speed and pressure than was observed when the external carotid clamp was released.

This proved to the speaker's satisfaction clinically that anastomosis had taken place between the two external carotid arteries and there was a decided flow of blood from the external into the internal carotid after common carotid ligation; in other words, the internal carotid becoming only an additional branch of the external after common carotid ligations.

Having had the experience of hemiplegia developing following the ligation

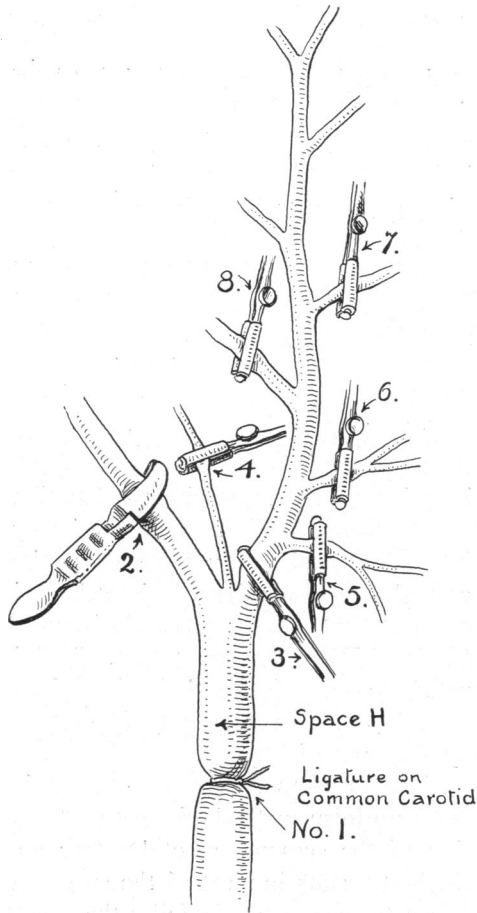


FIG. 1.—The Common Carotid Artery and its branches.

tion of the internal carotid, the speaker ligated the superior thyroid, the lingual, the facial, the occipital, and the ascending pharyngeal arteries and permitted the blood to come through the internal maxillary and temporal arteries, feeling that this would supply sufficient circulation to the brain.

Two months after the operation, the exophthalmus, while present, was so reduced that the patient could see; eye movements were normal; and there was no optic nerve degeneration. Neither the pulsation nor the bruit had returned. Now, on October seventh, which is four and one-half months after operation, the boy states he does not hear any sounds in his head, but thinks the eye has become a little prominent in the last two or three weeks.

Doctor Dorrance remarked that he was presenting this case as an illustration of a method of treating pulsating exophthalmos. It is known from autopsies, that most of these cases are due to communications between the internal carotid artery and the cavernous sinuses. A certain percentage of them apparently undergo spontaneous cures. Many cases reported in the literature have been greatly improved or cured by ligation of the common carotid artery alone. Ligation of the internal carotid artery cures a larger percentage, but unfortunately has a higher mortality; it is often followed by cerebral changes.

The speaker's suggestions in these cases would be as follows: To ligate the common carotid and if this does not cause the exophthalmos to recede and the bruit to permanently disappear, then depending upon the age and the amount of the arteriosclerosis, ligate at one time or in several stages the branches of the external carotid until the bruit disappears.

DR. JOHN H. JOYSON inquired why Doctor Dorrance did not ligate the internal carotid artery at the second operation. Ligation at the common carotid, previously done, had not been followed by any symptoms of cerebral anæmia; and this was presumptive evidence that the circulation through the Circle of Willis was competent. That is, if one did not attribute hemiplegia, which so often followed ligation of the common carotid to the detachment of embolus from the point of ligation, a theory emphasized in this country by Freeman of Denver.

DR. THOMAS A. SHALLOW remarked that up to the present time there is no uniform method of treating traumatic pulsating exophthalmos. Ligation of the common carotid artery on the side of the pulsation has given the best results in most of the successful cases, but even this radical method of treatment frequently fails; the reason for which is attributed, by some, to be due to a canalization of the artery at the site of ligation, thereby reëstablishing the normal flow of blood in the internal carotid artery. This may be the reason for failure in some cases, but it is not so in all cases.

Several years ago the speaker reported a case of bilateral pulsating exophthalmos before this Society. The right eye manifested the cardinal symptoms of this condition, the left eye to a lesser degree. He ligated the right common carotid artery. The bruit and hum immediately disappeared. This observation was made by stethoscopic examination on the operating table. There was a gradual recession of the eye and improvement in all of

## ANEURYSMS OF THE THORACIC AORTA AND INNOMINATE

his symptoms for several weeks. Then the bruit was again heard by stethoscopic aid, but the other symptoms and signs gradually improved and continued to do so for several months. Then he re-developed the original symptoms. Doctor Shallow concluded that he had established a collateral circulation from the left carotid artery across the Circle of Willis, this conclusion being based on the disappearance of the bruit and hum when the left common carotid was compressed in the root of his neck. He then ligated the left common carotid artery. The patient did not react from this ligation. He developed a high temperature and hemiplegia and died several days later.

At autopsy there was no canalization of the carotid artery first ligated. Sodium iodide was injected into the left common carotid artery above the ligation, and X-ray examination made of the head and the neck. The Circle of Willis was well shown, the right common carotid artery was filled with the solution, showing that the circulation was from above, downward, a reversal of current. He concluded, therefore, that failure of cure was due to reestablishment of the circulation from the other carotid artery. When success is not obtained by ligation of one common carotid artery, the other common carotid should be ligated after a number of months. The speaker hoped that Doctor Dorrance's method will obviate this radical procedure, which is attended with great risk of hemiplegia.

### TREATMENT OF ANEURYSMS OF THE THORACIC AORTA AND INNOMINATE ARTERY BY DISTAL ARTERIO-VENOUS ANASTOMOSIS

DR. PATRICK A. MCCARTHY read a paper with the above title, for which see page 161.

DR. GEORGE P. MULLER said that attempts to relieve the pain and pulsation which annoys the patient so much are always interesting. A number of years ago he introduced gold wire in a number of cases and sometimes obtained a measure of relief, but it was not always successful. About one month ago, he did one of these operations. The patient had a large swelling causing great pain and annoyance. The operation is simple enough. In the speaker's case the aneurysm came out on the neck and he was somewhat embarrassed on account of the short tense proximal segment. Immediately after the anastomosis he showed the transfer into the jugular vein. This case has been carefully studied by Doctor Wolfert from the cardiologic standpoint. Subsequently the patient went back to Porto Rico; but just before he went home he said that he could feel the aneurysm growing larger and it was on this account that he was anxious to leave. It seemed to the speaker in looking at the various operations for the treatment of aneurysm that the theory is a good one, but it would seem that there is a fly in the ointment. By various sympathetic procedures, he believed that just as much will be accomplished. In Doctor Muller's opinion this always will prove to be an operation of relief rather than cure and eventually these cases will relapse and die just as the wired cases did.