

TRANSACTIONS

OF THE

PHILADELPHIA ACADEMY OF SURGERY

STATED MEETING HELD NOVEMBER 6, 1933

The Vice-President, DR. WALTER E. LEE, in the Chair

CALVIN M. SMYTH, JR., M.D., Recorder

ACUTE STREPTOCOCCIC OSTEOMYELITIS FOLLOWING A SIMPLE FRACTURE OF THE FEMUR

DR. WALTER ESTELL LEE and DR. J. T. F. GALLAGHER reported the case of a girl of ten years, previously in good health, who was admitted to the Pennsylvania Hospital November 6, 1932, immediately following an automobile accident. There was an oblique fracture of the left femur about six inches below the greater trochanter (Fig. 1), in which the distal fragment was angulated fifteen degrees outward. There was a large hæmatoma at the site of the fracture but no break in the skin. The extremity was suspended in a Russell extension apparatus and the course was uneventful for the first three days following admission, when the temperature rose to 101° F., the pulse became rapid and the child became irrational. Examination of the head revealed a decrease in the superficial swelling and contusions of the scalp, but the left ear-drum showed a fiery injection along the handle of the malleolus. The drum did not bulge, however, and it was not incised. The right ear was not remarkable. The patient ran a hectic fever which had gradually subsided ten days after the onset with a disappearance of the signs of otitis and an apparent general improvement.

On the thirteenth day the temperature again rose sharply and there was extreme tenderness with moderate swelling and inflammation at the site of the fracture. A fluctuant mass pointed on the postero-lateral surface of the thigh which was aspirated and 320 cubic centimetres of thick grayish pus mixed with blood were withdrawn. Hæmolytic streptococci grew on the culture. Following the aspiration the swelling promptly reappeared and another tap was made, containing 350 cubic centimetres of pus and blood similar to that obtained at the first aspiration. The hectic fever continued, the fluctuant mass reappeared and two weeks after the development of the infected hæmatoma an open drainage was done at the site of fracture. Under avertin anæsthesia incisions were made along the lateral and posterior surfaces of the thigh, and a large amount of grayish-yellow pus evacuated from beneath the subfascial planes and periosteum. The periosteum was found to be stripped back from the ends of both fragments for a considerable distance. Pus also escaped from the medullary cavity and there was no evidence of bony union. Hæmorrhage from the periosteum was profuse and the vessels could not be ligated due to the extensive necrosis of the tissues. Hæmostats were left in place and the wound packed with gauze saturated with 5 per cent. solution of dichloramine-T. The patient left the operating room in profound shock and was not expected to live.

She rallied somewhat after the intravenous administration of 5 per cent. glucose in saline and during the following days she received repeated small transfusions of citrated blood. The hæmostats were removed four days post-operatively and there was no hæmorrhage, although the wounds continued to

drain pus freely. Carrell-Dakin tubes were inserted and irrigations with normal saline solution every two hours were continued for five days, when the temperature returned to normal. The wounds healed by granulation, and bony union began to take place. The patient was removed from the extension apparatus 109 days following the accident and discharged wearing a leg brace and in excellent general condition with sufficient callus to allow active motion without weight-bearing. There was perfect alignment of the shaft of the femur with no shortening of the leg. Along the lateral and anterior aspects, however, the callus was still deficient, and there was a small sequestrum with non-union of the callus at this point. (Fig. 2.)

Eight months following the injury the child resumed her normal activities without the brace. The callus increased in density but a small sinus running through the site of the fracture containing sequestra persisted. (Fig. 3.) Ten months following the accident the patient spontaneously expelled a small spicule of bone which on microscopical examination revealed the presence of Gram-positive cocci. Following this the wound healed promptly, but only last week the sinus tract reopened with slight drainage, indicating the presence of other sequestra.

It is well known that acute osteomyelitis in adolescence is essentially a blood-borne disease, localizing in the metaphyses of long bones. An important cause of such localization was determined by Lexer, when he demonstrated the loop arrangement of the capillary vessels in the metaphysis which accounts for the slowing up of the circulation and thus favoring the lodgment of bacterial emboli. In early cases of osteomyelitis Clarence Starr demonstrated that the initial lesion is always in the juxta-epiphyseal region and follows varying degrees of epiphyseal separation. In adults there is less tendency to well-defined localization of an osteomyelitis and the disease occurs much less frequently after ossification of the epiphyses has taken place. Trauma undoubtedly plays an important rôle.

The case here reported is one of acute streptococcic osteomyelitis which followed a simple fracture of the shaft of the left femur. It exemplifies the hæmatogenous origin of the disease and the determination of the site by the trauma. It is also worthy of note as a localized osteomyelitis compared with the massive infection of bone that always takes place where the intramedullary pressure is not promptly relieved. A survey of the literature indicates the rarity of such an infection although following compound fractures and amputations it is common enough.

DR. WALTER ESTELL LEE remarked that the localization of this infection to the immediate area of the fracture is in marked contrast to the massive osteomyelitis which usually develops in pyogenic suppuration of the growing long bones. We have taught for some years that this massive destruction of the bone is primarily the result of the increase in the intramedullary pressure without the cavity of the rigid bony tube, resulting from the inflammatory response, to a point greater than that of the blood-pressure within the nutrient vessels. With the cutting off of the blood supply massive death of the diaphysis rapidly occurs. Infection, though at first a localized process, rapidly involves the necrotic bone. In this case the medullary cavity was

ACUTE STREPTOCOCCIC OSTEOMYELITIS

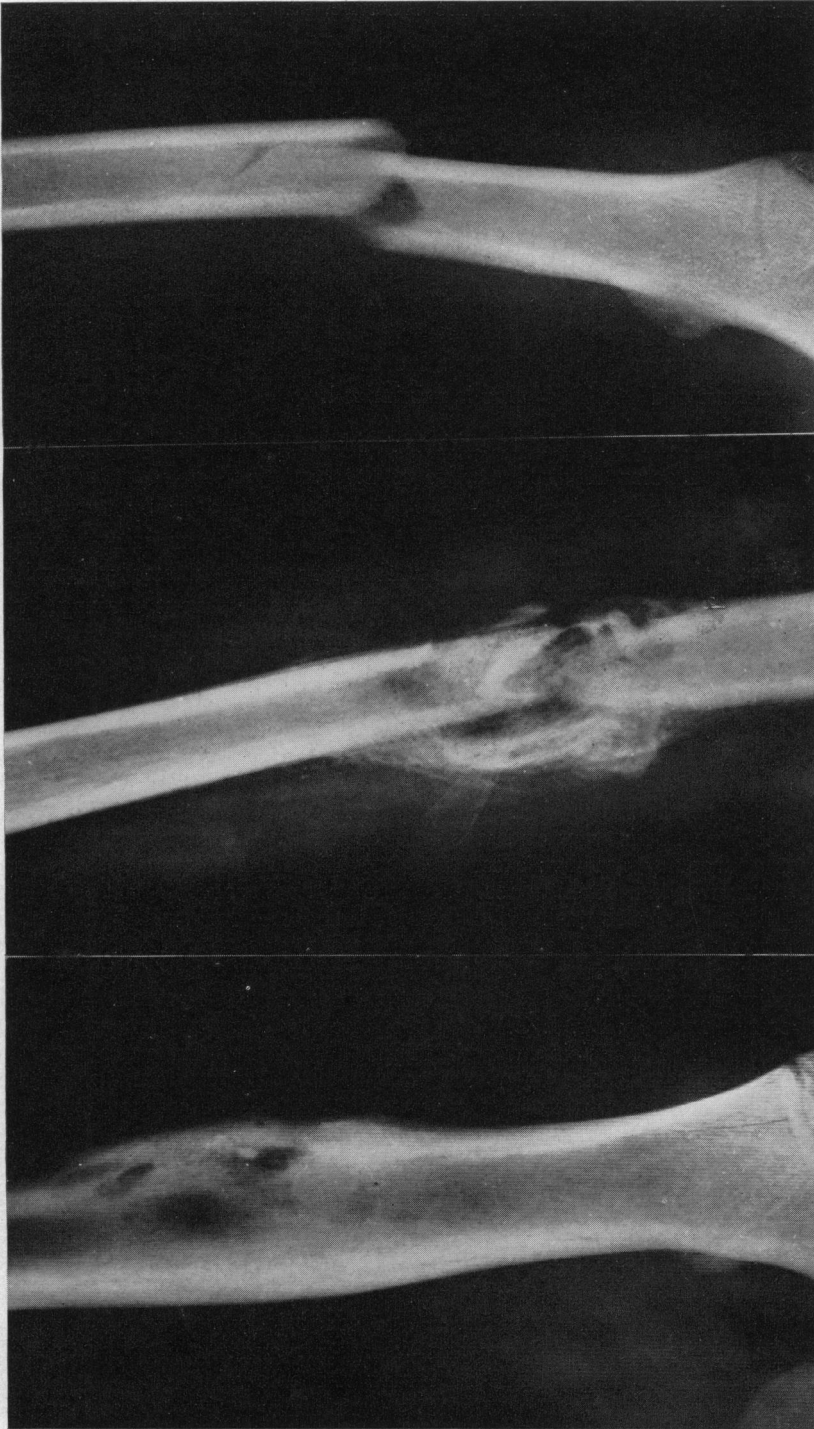

Fig. 1.—Röntgenogram at time of accident, showing oblique fracture at junction of middle and upper thirds of the left femur.

Fig. 2.—Röntgenogram three months following accident and after surgical wounds had healed, showing unhealthy callus and bone absorption at site of fracture.

Fig. 3.—Röntgenogram eleven months following accident, showing dense callus formation with sinus tracts and sequestra at line of fracture not sufficient, however, to mar the strength of the bone.

decompressed at the time of the fracture, and when the blood-stream infection became localized at this point, although an increased blood supply was brought to the part, it escaped from within the bony cavity through the line of fracture, and therefore, there was no abnormal increase in intramedullary pressure. No better research could have been planned than that provided by this clinical case in which, because of decompression of the medullary cavity of the bone the infection was localized. This certainly seems to bear out our belief that the amount of destruction of bone in pyogenic osteomyelitis of the growing long bones is in direct proportion to the duration of time that increased intramedullary pressure is allowed to continue, and that by very prompt decompression of the medullary cavity by drilling holes in the cortex or by cutting a trough through the cortex, the blood supply is restored to the cortex and death of bone is minimized.

DR. HENRY P. BROWN said that a young man of thirty years was admitted to Doctor Hodge's service at the Presbyterian Hospital with a fractured femur which could not be reduced satisfactorily by traction. About seven or eight days later, on open reduction, a collection of serum was found between the ends of bone from which was obtained staphylococci in pure culture. After reduction the wound was closed without drainage, no infection followed and the patient had a primary union.

IMPERFORATE ANUS

DR. I. S. RAVDIN presented a boy seven years of age who when forty-eight hours old was admitted in the service of Dr. G. P. Muller in the Hospital of the University of Pennsylvania with the diagnosis of imperforate anus. The child was born on the second of February, 1926. The labor was about nine hours long and was unattended by any difficulties. At birth he was apparently healthy; after two days the child seemed well but no bowel movements had taken place. Examination revealed that he had no anal opening. He was well developed and had no deformities except for the absence of an anal opening. The abdomen was rotund and distended, and moderately tympanitic. Peristalsis was hyperactive. There was no anal opening nor any sign of a pit or bulge in the perineal region. The child was operated upon by Dr. I. C. Ravdin on the day of admission, with "sugar-tit" anaesthesia. An incision was made in the perineum from the posterior edge of the scrotum to the tip of the coccyx. By careful dissection and keeping quite close to the curve of the coccyx and sacrum, the incision was carried up to the cul-de-sac of the peritoneum. At that time no bulging of the non-descended rectum was noticeable. By measurement they had gone nearly six centimetres. After a little more dissection a bulge during inspiration was noticeable and there was finally disclosed a blue mass bulging into the wound. (Fig. 4.) This was opened and about 250 cubic centimetres of meconium with gas were immediately evacuated. After evacuation of the bowel it was possible to bring the gut down to the edges of the wound where it was sutured with six sutures of black silk. A piece of iodoform packing was put on either side of the wound between the rectum and the perineal tissues and a rubber tube was inserted into the lumen of the bowel.

At the conclusion of the operation the child was given 50 cubic centimeters of citrated blood by intraperitoneal route.

IMPERFORATE ANUS

No inhalation anæsthesia was given at any time during the operation and the child did not seem to suffer any great amount of pain; in fact he slept during the greater part of the time.

Two days after the operation the bowels moved three times during the night. The temperature rose sharply to 105° F. but the general condition was satisfactory. It was taking mother's milk—two ounces, every three hours. On the fourth day following the operation the condition was satisfactory although the child continued to run a temperature of about 103° F. The bowels moved two or three times that day. On the sixth post-operative day the tube and the skin stitches were removed. The wound was clean. The temperature rose to 105° F. again on this day but the general condition seemed fair. The lungs remained clear. Two days following this the temperature fell to 100° F. Ten days after operation the wound was clean and healing nicely, and the temperature was normal. There was still a granulating surface but the bowels moved regularly. From the time of discharge dilatation of the anal opening was practised but the stricture became increasingly firm.

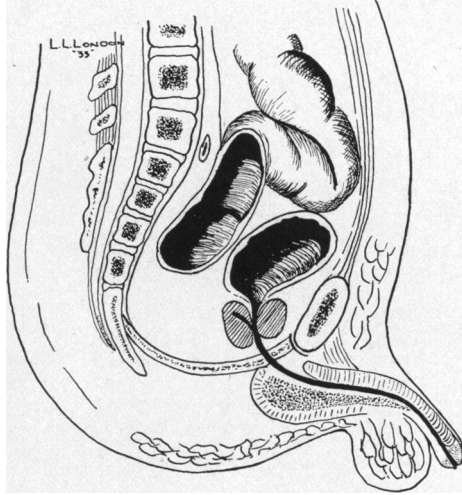


FIG. 4.—Terminal state of rectum as disclosed at operation.

On June 1, 1931, the child was again admitted to the hospital with a rectal stricture. On the following day a plastic operation was performed. The stricture on one-half of the anus was excised and the mucous membrane sutured to the skin around the anus. Fourteen days later a similar operation was done at which time was removed the remainder of the scar which was causing the stricture.

The child has grown normally and is in excellent condition. Except when his movements are loose he controls his evacuations. He attends school and participates in games with his schoolmates.

While there has been an increasing tendency to resort to inguinal colostomy for the primary operation the perineal route would seem to be the preferable exposure unless the blind end of the colon hangs free in the peritoneal cavity. If adequate exposure is obtained and the tissues are gently handled the operation should not be attended by much shock.

IMPERFORATE ANUS—END-RESULT

DR. WALTER ESTELL LEE and DR. N. P. SHUMWAY presented a male infant born in the Philadelphia Lying-In Hospital November 6, 1931. He was the first child of rather elderly parents. The delivery was prolonged and rather severe by reason of a breech presentation. Upon admission to the nursery on attempting to obtain the rectal temperature absence of the anus was discovered; this was reported immediately to the attending physician but because of the child's general condition it was determined to wait for some improvement before attempting surgical relief. After fourteen hours' observation there was some general improvement, but abdominal distention

was rapidly increasing and there was slight but persistent regurgitation of fluids; the child was restless and cried continually. Examination at the time revealed total absence of an anal dimple and there was no bulging or thrust of the perineum upon straining. Colostomy was, therefore, performed fifteen hours after delivery. Six and one-half hours later there was sufficient plastic peritoneal reaction to have securely walled off the abdominal cavity and the gut was opened longitudinally with a nasal tip cautery. There was immediate discharge of meconium. The supporting catheter was removed three days later.

The patient had no post-operative reaction and his subsequent course

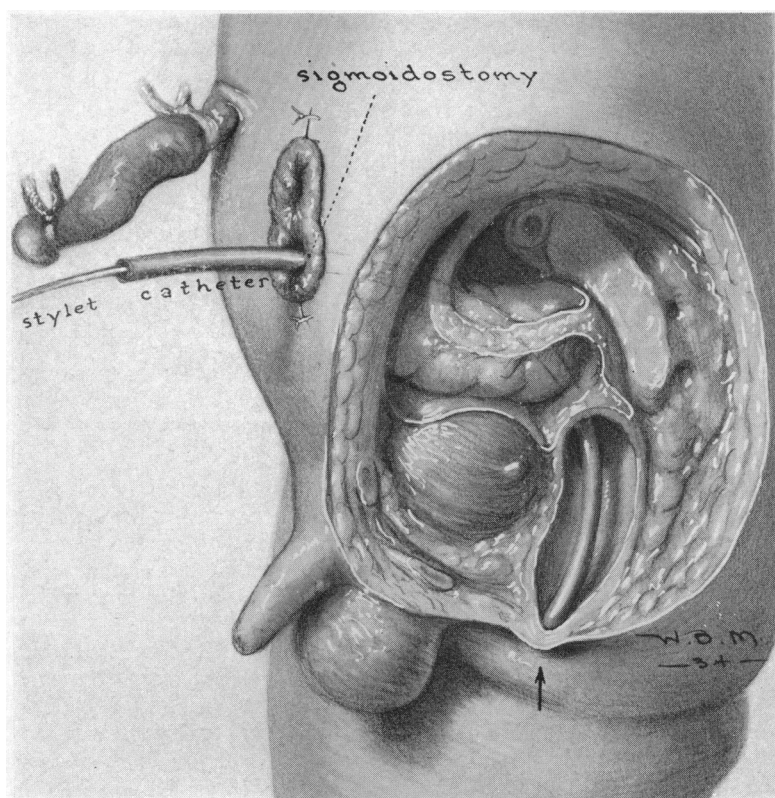


FIG. 5.—Sigmoidostomy subsequently followed by perineal section under guidance of a catheter introduced on a stilet through the opening in the sigmoid.

was most satisfactory, showing a progressive gain in weight. The only complication was a tendency toward excoriation of the skin about the wound. This was best controlled by a liberal use of vaseline-gauze dressings and the institution of an acidophilus milk formula.

On the thirty-fourth day after delivery a small catheter, No. 10F, was inserted through the colostomy opening into the distal segment of the bowel; through this, iodized oil was injected with a resulting visualization of the rectal pouch. By comparison with an opaque marker on the perineum the rectum appeared to be about one inch away; the pouch was quite clearly seen and there seemed to be a conical extension beyond the main bulb toward the anal region.

IMPERFORATE ANUS

An attempt was made to connect the rectum with the perineum on the forty-first day of life, anæsthesia being successfully obtained with whiskey water. Under fluoroscopical control a No. 16F soft rubber catheter with blunt tip was inserted into the lower loop of the sigmoid through the colostomy; some difficulty was met with in pushing the catheter into the rectum because of coiling, which tendency was obviated by threading a fine wire stylet into the tube, which also added to its opacity to the X-ray, affording very satisfactory visualization. (Fig. 5.) The exact position of the rectum having been determined by this means, incision was then made through the perineum. No muscular tissue being met with, the dissection was carried toward the rectum until the catheter could be readily palpated and finally grasped and brought out through the wound—a distance of approximately three centimetres. The rectum was not mobilized and the perineal wound was closed about the catheter with two skin sutures of dermol. By this procedure the possibility of opening into the peritoneal cavity was prevented. There was no shock post-operatively and there was a rise of temperature to only 100° on the following day; other than this there was no untoward reaction. The catheter was removed at the end of eleven days and another of the same calibre reinserted through the colostomy wound; this procedure was followed at weekly intervals thereafter for the first month after operation, when the catheter was no longer inserted from above, that portion connecting the rectum with the anus alone being maintained. On the forty-fifth day after perineoplasty there were free fæcal passages by rectum. Three months after operation the child was discharged from the hospital to be followed in the Surgical Out-Patient Department; there the routine has been a weekly insertion of a mushroom catheter into the rectum.

Examination at the present date shows a well-developed and active child, weight twenty-eight pounds, with a left-side colostomy wound which occasionally discharges fæcal matter. The rectal examination reveals a tract which will just admit the little finger; its wall is covered with rectal mucous membrane extending almost to the perineum. The surrounding tissue is firm and indicates that continual dilatation will be required to maintain its patency. There is, of course, no control of the evacuations since the catheter is still being inserted at weekly intervals.

Congenital imperforate anus is not a common complication of infancy, occurring but once in 5,000 to 10,000 births, however, it is a condition which being present usually demands immediate surgical treatment. Like most other congenital defects it is frequently complicated by atresia of some other portion of the intestinal tract, by cardiac malformations, or genital deformities which as a rule make the prognosis poor; even without a second deformity the outlook is not exceptionally good, for many writers upon the subject are of the opinion that the rectal anomaly itself exerts a retarding effect on the foetal development in utero. This is an important factor in the determination of the type of surgical procedure to be used, in that one is dealing with a patient who demands the least trauma possible.

The etiology of the condition lies in the embryological development of the portion of the gut at fault; this fact was most clearly elucidated by Keith in 1908, and it was upon this basis that he proposed a most satisfactory classification of the various types of deformity found in this region. Up until the tenth or twelfth week of foetal life the hind-gut and the Wolffian

body form a common cloaca; these rapidly separate and the hind-gut pouches down to meet an invagination of the proctodeum which forms the anus, fusion taking place at about the twelfth week. This process is based upon the evolutionary development of the vertebrates and really amounts to the migration of the anus from an intracloacal position, as found in the frog, to an extracloacal or perineal position. With this as a basis we are able to determine the three groups into which all deformities must fall. First: those in which the rectum empties into the urogenital tract; second, those in which the hind-gut is imperfect; third, in which the proctodeum is imperfect. It is obvious from the development of the region that any one or all three may occur with any combination of them together, and when it is further realized that the internal and external sphincters are a part of the proctodeum we must conclude that the external examination of the parts does not give any indication as to the exact condition present. Thus we may have a normally formed anus and yet the rectum be anywhere from one-sixteenth of an inch to two inches away from the perineum. This is the second fact which must influence our decision in the matter of surgical approach.

Limiting the discussion to the condition found in the case reported, namely, a combination of the second and third types, it may be said that the symptomatology of the condition varies with the time elapsing between birth and the surgical intervention resorted to; that is, if the period is lengthy the cardinal signs and symptoms of acute intestinal obstruction may be expected.

Mortality in this condition is rather high, death being certain if no operative procedure is resorted to; the figures for those operated upon give as a rule a total mortality of about 25 per cent. Brenner, reporting sixty-one cases, gave 26.2 per cent. although of these but three were of the type with complete occlusion. Of 104 cases collected from the more recent literature the total mortality was 20.2 per cent.

Of the various operations performed for the relief of imperforate anus the one which suggests itself most readily is that first employed by d'Amussat, which consists in a dissection of the perineum with search for the rectum and its mobilization so that it may be brought down to its proper position. This method is the one chiefly favored. The second route is that of colostomy with perineoplasty. A third method is that of colostomy with secondary perineoplasty. A fourth method is mentioned and condemned by all writers, that of blindly searching for the rectum with a trocar. Here the danger lies in piercing Douglas' pouch, which often lies between the perineum and the rectum, with subsequent peritonitis.

The first method described is advocated by the majority of men who have written upon the matter, and in a greater part of the statistics it has had the lowest mortality; thus in Brenner's series of twenty-nine cases operated on by direct perineoplasty the mortality was 24 per cent.; of the eleven in whom colostomy was performed the deaths amounted to 66 per cent. However, it was our feeling that in general the statistics against primary colostomy

are deceiving in that often it had been resorted to only after perineal search had failed, and consequently the child had been subject to a great deal of trauma. With this in mind we have grouped the 104 cases from recent reports into those in whom perineorrhaphy was primary, sixty-three with a mortality of 22.2 per cent.; colostomy, twenty-two with a mortality of 18 per cent.; and the combined, sixteen with a mortality of 68.7 per cent. In this it is seen that if the last two are combined the mortality for colostomy is 39.4 per cent., whereas the corrected deaths are actually lower than the 22 per cent. found in the type of operation chiefly advocated; moreover the perineal route is successful in only 80 per cent. of the cases, the remainder requiring colostomy as a last resort. Recently, however, Wangenstein and Rice have described a method of determining the position of the rectum by X-ray which should reduce the mortality for the perineal route; they advocate the placing of the child in a head-down position in order to allow an accumulation of gas in the rectal pouch with subsequent röntgen examination to definitely localize the end of the gut. This entails a certain delay in operation, at least ten to twelve hours being required for the formation of a sufficient quantity of gas to outline the rectum; and while many believe that operation may be postponed for twenty-four to forty-eight hours, yet this idea is certainly contrary to the principles of surgery in the treatment of intestinal obstruction. Further, the intestinal tract of the child during the first thirty-six hours of life is generally thought to be sterile, and since gas to be present must be preceded by the gas-forming organisms, operation by this method is being put off until there is an infected field, a totally irrational procedure.

Primary colostomy, as performed in the case reported by us reveal no delay, was borne well by the patient, and permitted subsequent use of a method by which the rectum was accurately visualized before and during the secondary perineal repair.

The literature contains mention of similar visualization of the rectal pouch with an X-ray-opaque substance injected through the colostomy wound, by Doctor Hirschman of New York while discussing a paper by Doctor Landsman in 1926. We have not found any report of the use of an opaque catheter and fluoroscope as was done in our case at operation.

DR. I. S. RAVDIN said that his patient, of course, had no sphincter because there never had been any. The ideal thing to do for this child is the operation for anal incontinence described under several names but which should probably be credited to Harvey Stone. This operation consists in slinging two strips of fascia around the anus by passing them subcutaneously from the gluteus maximus muscles; the strips pass around the sides of the anus opposite to the muscles from which they start and interlock with each other. Control is afforded by contraction of the glutei, which in turn tightens the fascial ring. The speaker proposes to do this operation sometime in the near future.

PHILADELPHIA ACADEMY OF SURGERY

DR. GEORGE M. DORRANCE mentioned a patient who is at present under his care in whom the perineal operation was unsuccessfully attempted. On opening the abdomen the blind end of the bowel was found to be adherent to the bladder and colostomy, was, therefore, performed. Now there is a prolapse of about eight inches of sigmoid through the abdominal wound.

FRACTURES OF THE CAPITELLUM OF THE HUMERUS

DR. WALTER ESTELL LEE and, by invitation, DR. THOMAS SUMMEY, read a paper with the above title for which see vol. 99, page 497.

SPINAL ANALGESIA—A REPORT OF FIFTEEN HUNDRED CASES

DR. ORVILLE KING, by invitation, read a paper with the above title.

PRIMARY CARCINOMA OF THE COMMON BILE-DUCT

DR. WALTER ESTELL LEE and, by invitation, DR. H. P. TOTTEN read a paper with the above title.

TUBERCULOSIS OF THE BREAST

DR. WALTER ESTELL LEE and, by invitation, DR. HARRY G. FLOYD read a paper with the above title for which see vol. 99, page 753.

DR. I. S. RAVDIN recalled a case operated upon by the late John B. Deaver in 1920 which had been operated upon previously by E. G. Alexander for a breast tumor. Examination of the tissue removed by Doctor Alexander showed adeno-carcinoma. Six months later an ulcerated lesion about three centimetres in diameter appeared on the same breast. Doctor Deaver did a radical resection of the breast. The histological studies disclosed an associated carcinoma and tuberculosis in the same breast. In 1854 Rokitansky states that tuberculosis and carcinoma in the same individual, and more especially in the same organ, were incompatible. This has since been shown to be a fallacy.

DR. STEWART RODMAN recalled a case that occurred in his father's practice which has proven the association of tuberculosis and carcinoma in the same breast. The pathological diagnosis was confirmed by the late Doctor Copeland.

In so far as the treatment is concerned, most of those who have written on this subject advise resection of the diseased areas. As he had seen recurrences following this procedure, the speaker now practises and believes it to be the operation of choice—simple amputation.